

Global Clinical Case Contest 2021-2022

2.
Place

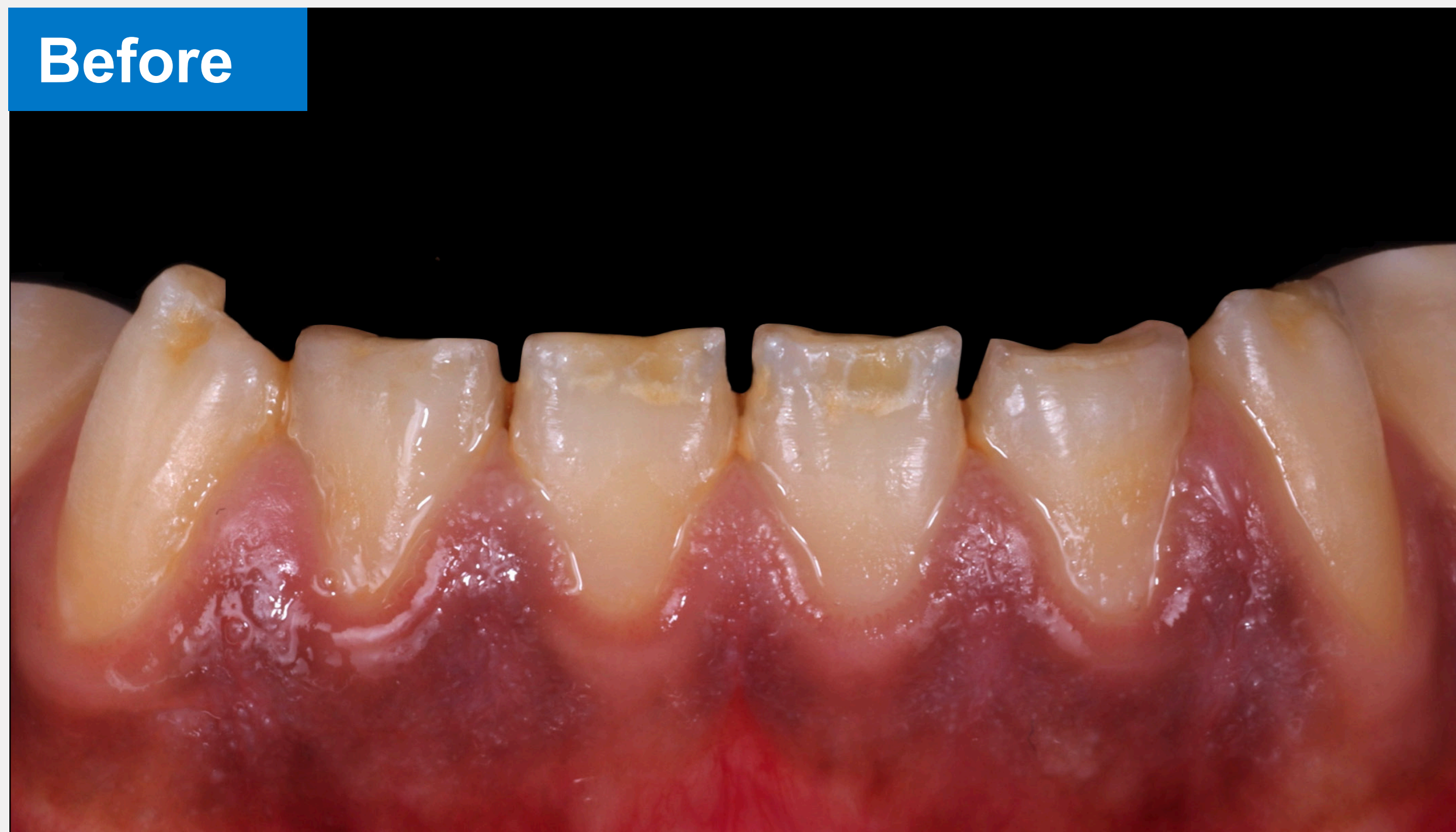

Student:
Bilal BALBZIOUI
Tutor:
Dr Francois REITZER
University:
Strasbourg
Country:
FRANCE

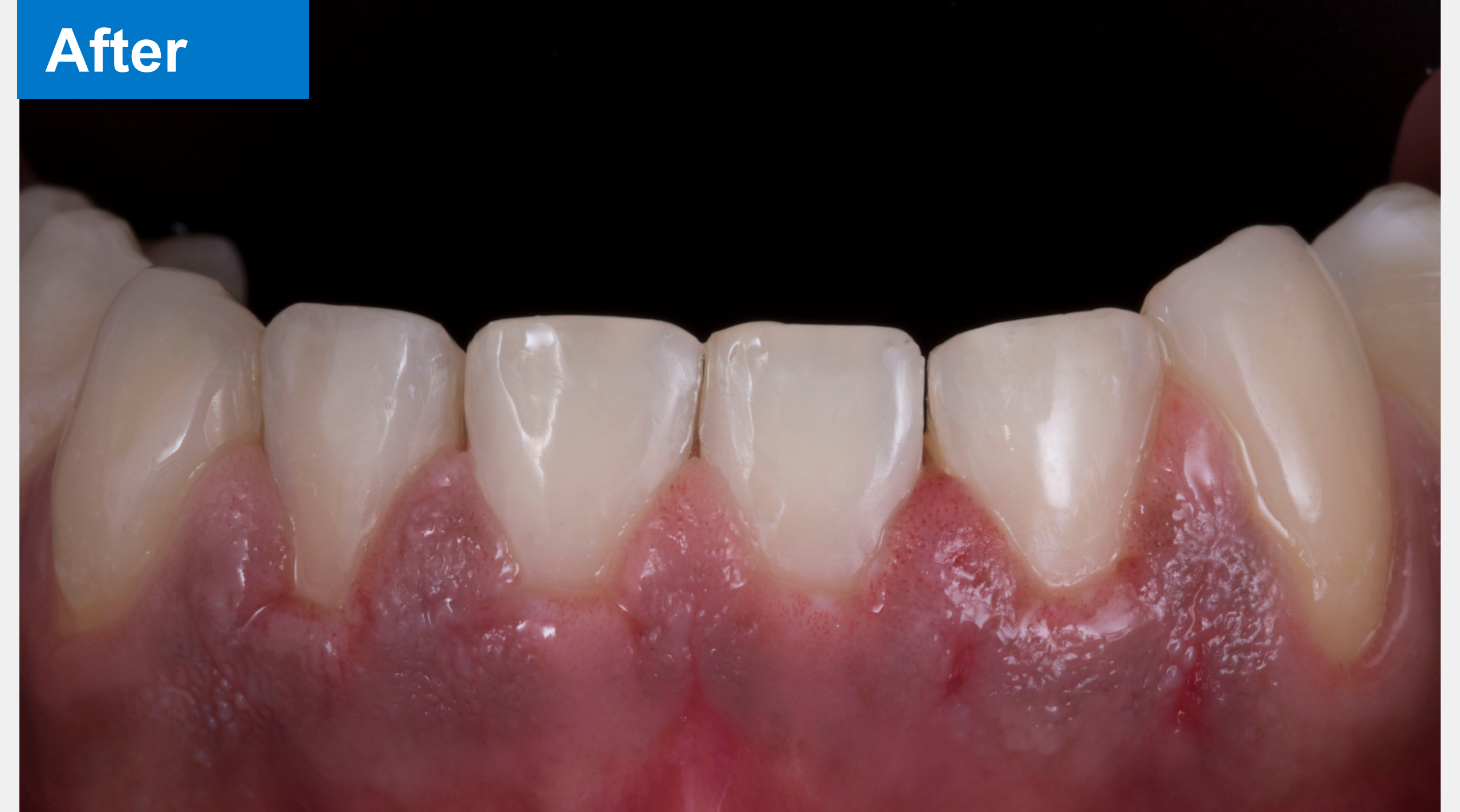

Introduction to the case

A 22 year old patient wishes to have a global esthetic treatment in order to correct shape anomalies of the mandibular incisivo-canine area. The clinical evaluation reveals an enamel defect, classified as an chronological hypoplasia of the enamel .

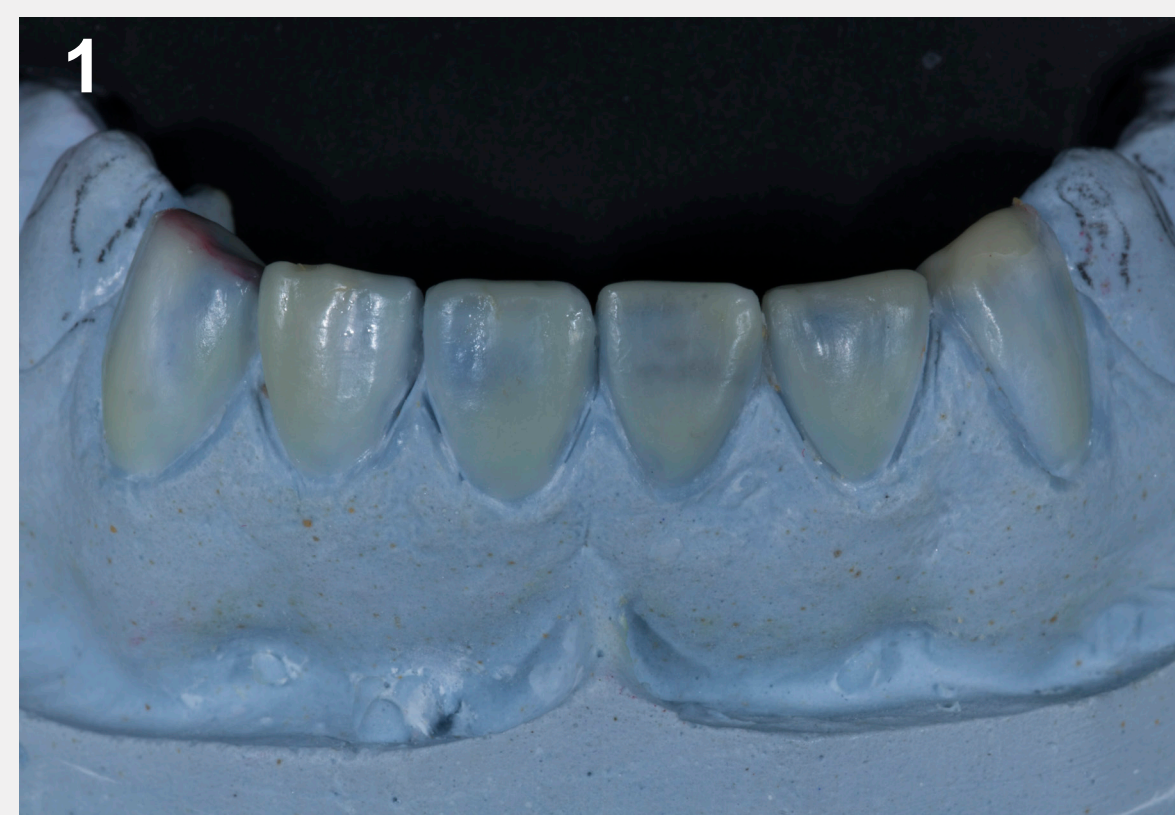

The teeth anatomy present a shape and shade disorder. The esthetic and functional treatment has to be carried out on the 6 anterior teeth.



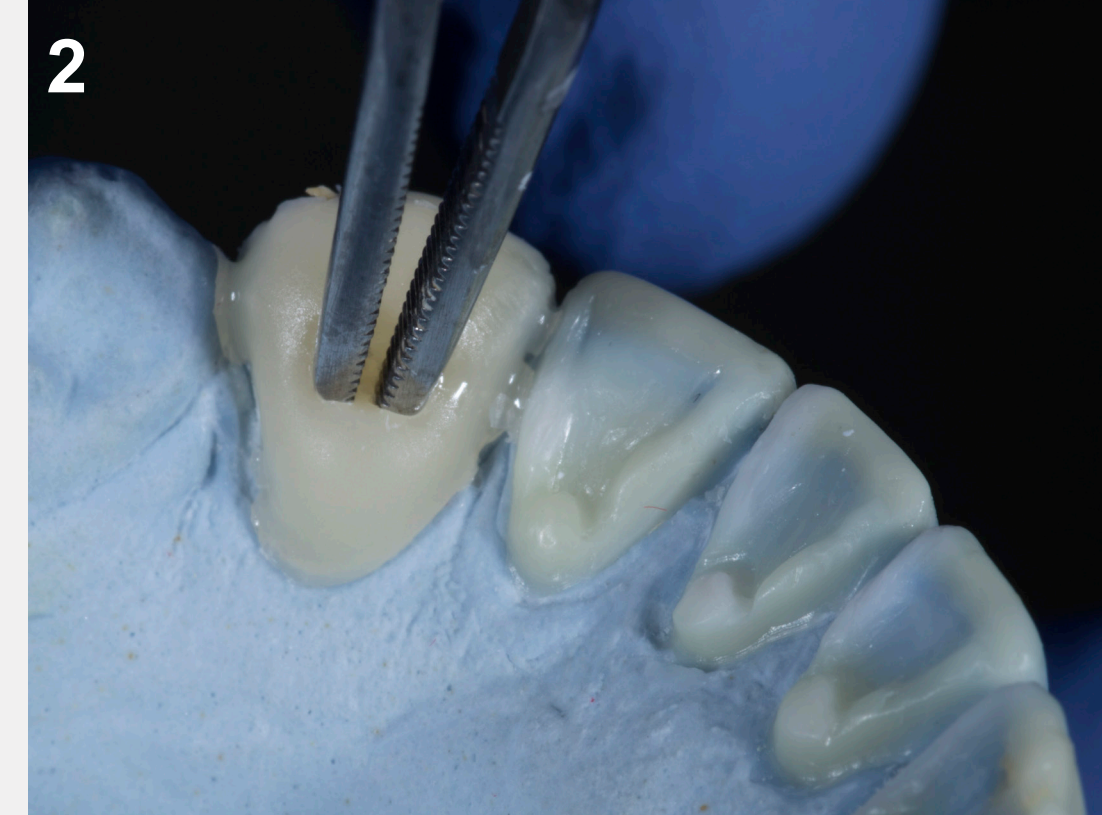
The conservative treatment allowed to restore natural shape and color through an innovative technique with direct composites restorations.

Treatment steps



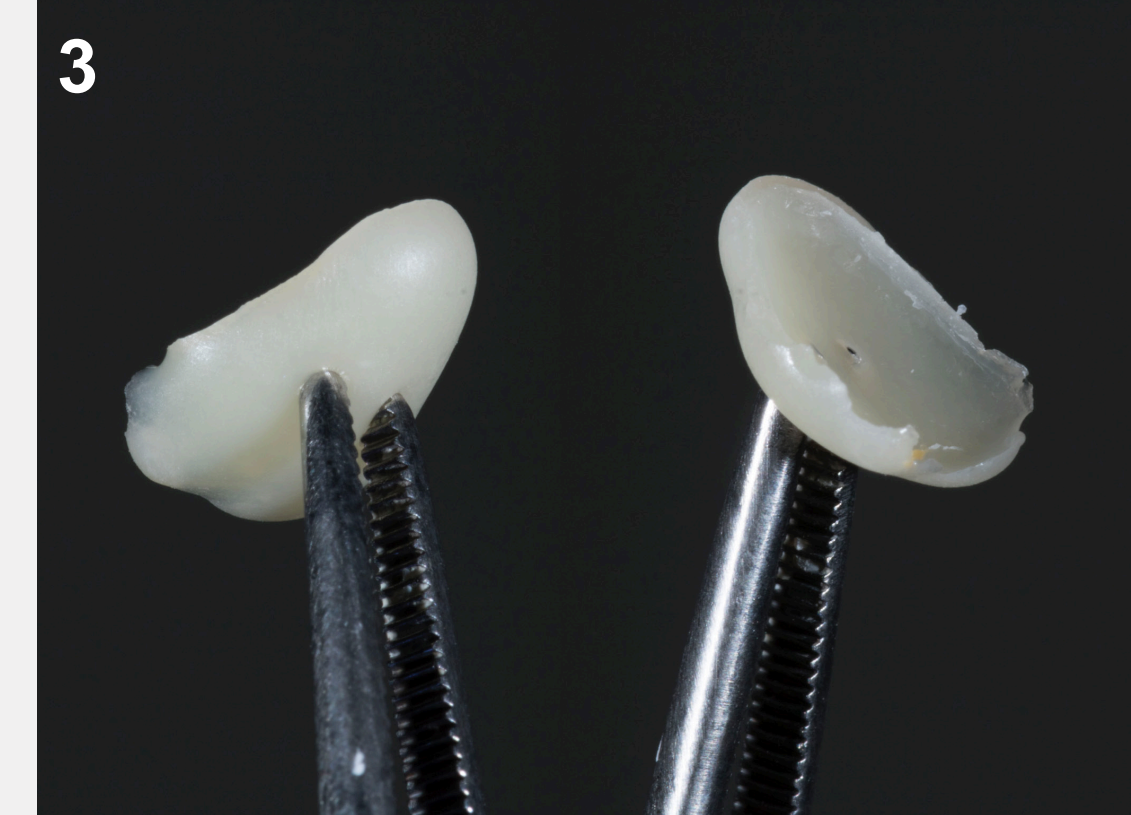Step 1 – Wax Up

The aesthetic project is based on a wax-up. The small wax thickness, necessary to modify the shape, leads to use a direct composite bonding without preparation of the tooth surface.



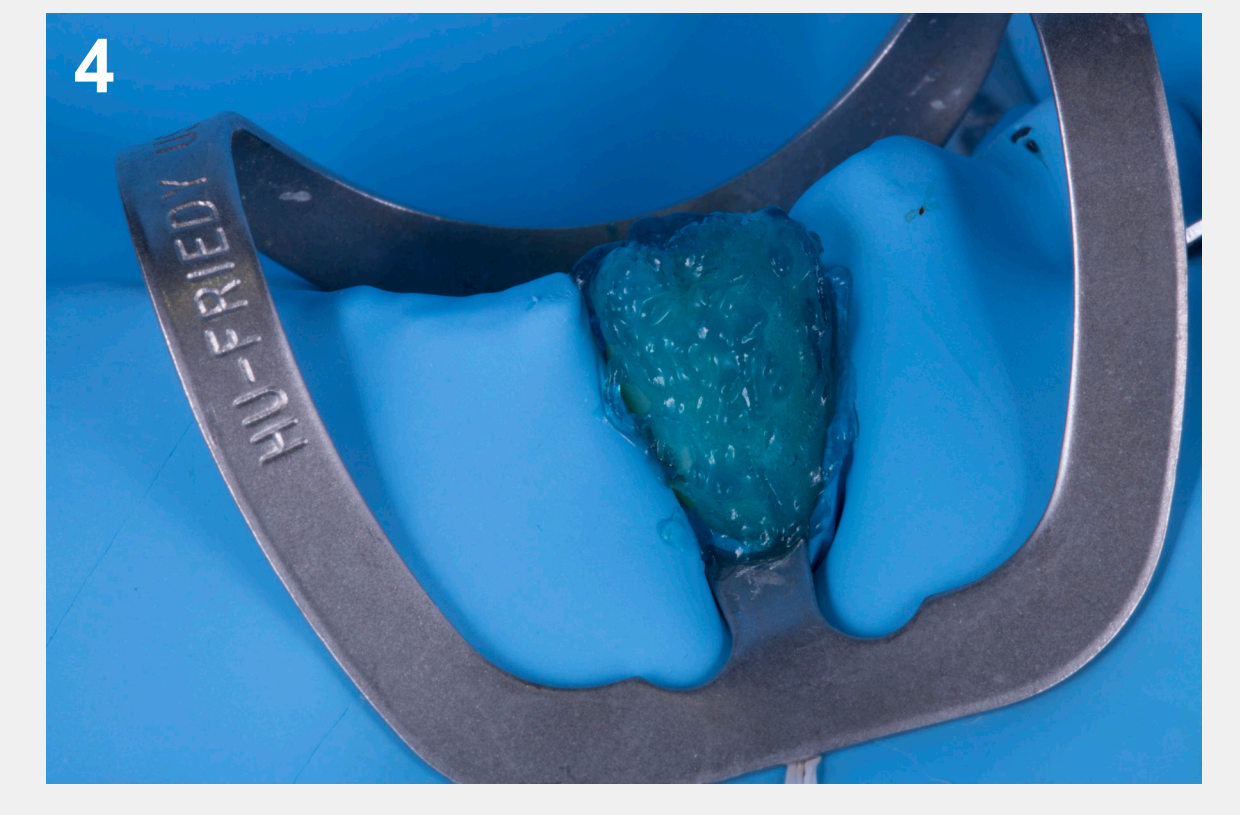
Step 2 – Stamp for anatomical transfer

The esthetic project can be precisely transferred with lingual and buccal stamps. These „shells“ are made with flowable composite on the wax up and cured.



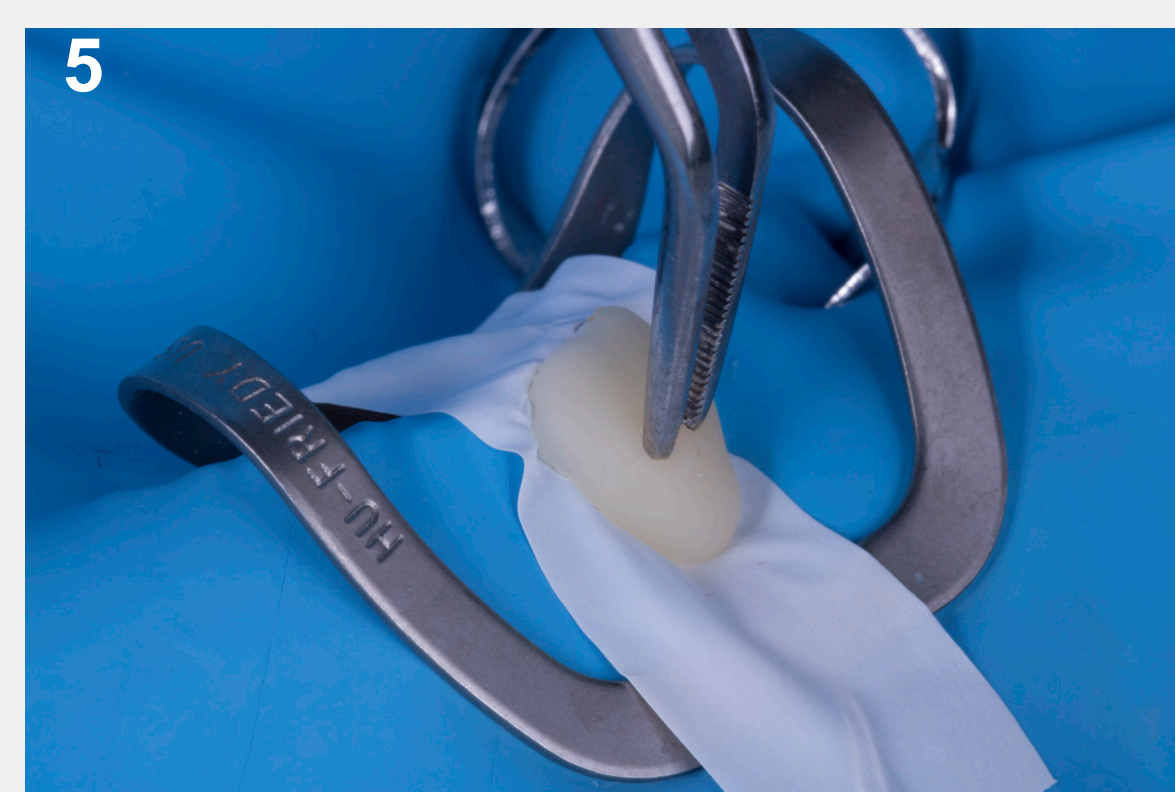Step 3 – Shell handling

The tweezers are thoroughly placed during the curing process, to facilitate the repositioning of the stamp.



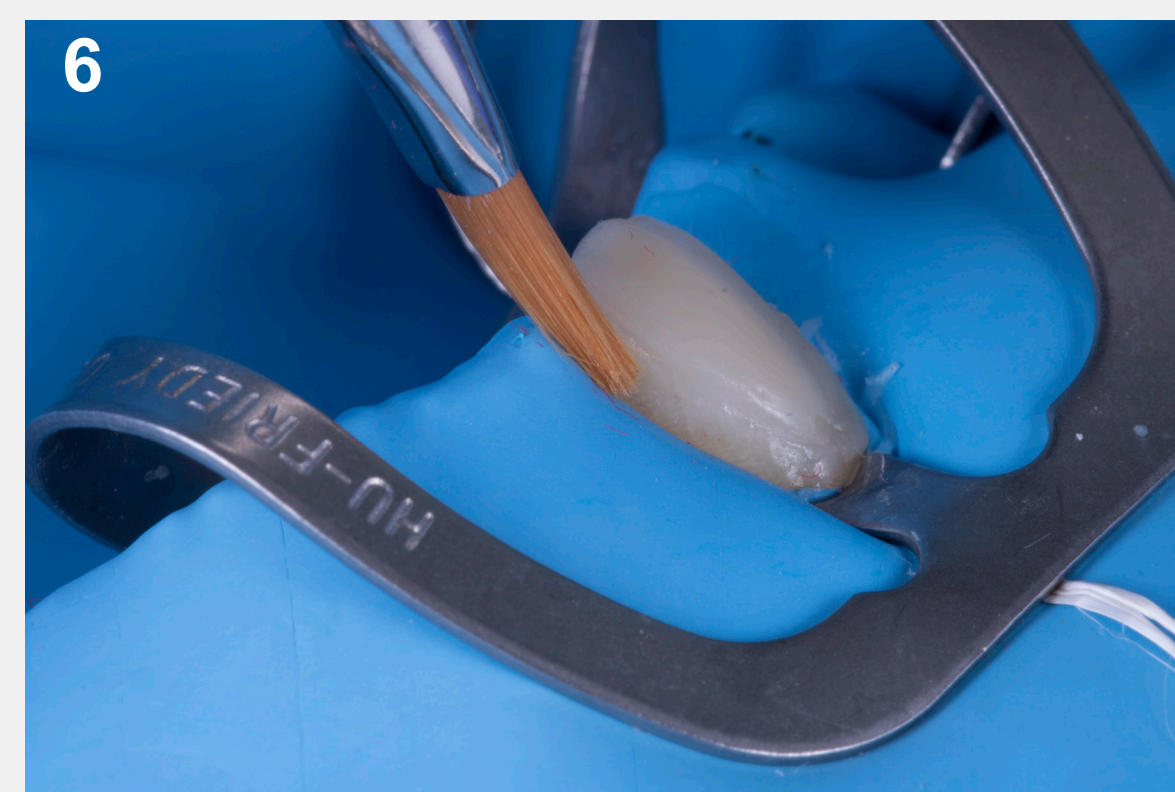Step 4 – Total etch

The restorative treatment is done tooth by tooth. The single operating field facilitates the clinical procedures. The bonding process is achieved.



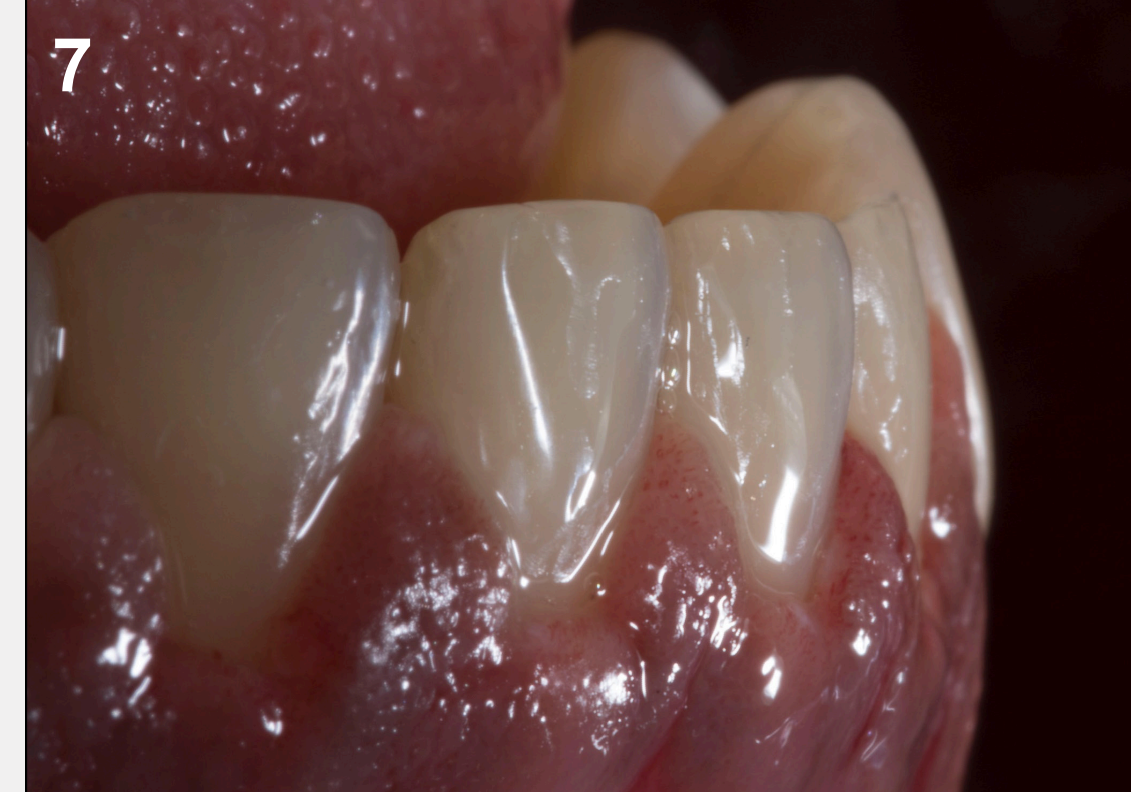Step 5 – The composite enamel build-up

1. An enamel layer of composite is applied on the buccal side of the tooth.
2. A piece of teflon is placed on the surface of the resin.
3. Then the stamp is pressed until a perfect setting on the margin of the tooth.



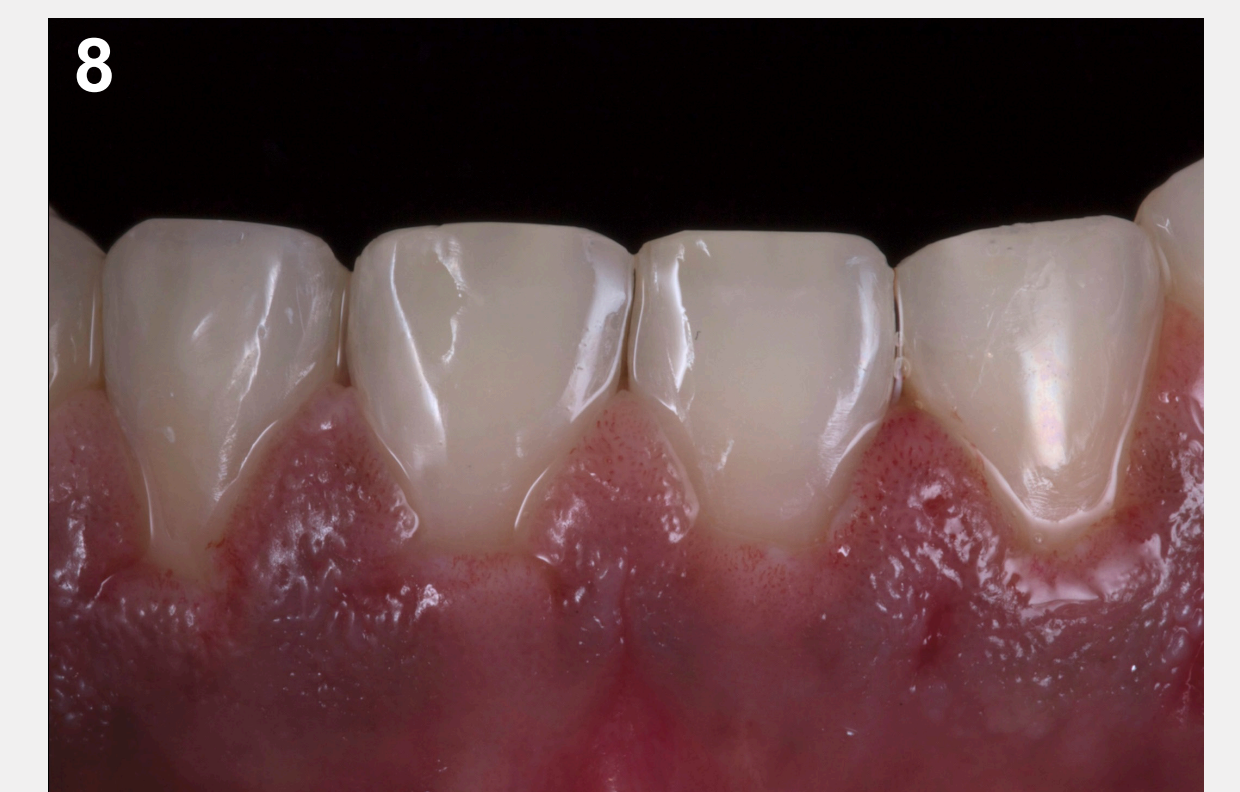Step 6 – Contouring, control and curing

Before curing, the stamp is removed and the excess of composite are eliminated with a brush, after control, the curing process can start.



Step 7 – Duplication on the other teeth

The same procedure is duplicated on the other teeth, and the finishing steps are carried out on each tooth.



Step 8 – Final result

The composite restorations give an esthetic and functional integration.

Material and Method

- Realization of an aesthetic project with wax up.
- Realization of the pads/stamps in composite flow (SDR flow +) directly on the palatal and vestibular faces of each tooth.
- Placement of the operating field, etching with 37% DeTrey® Conditioner 36 for 40 seconds per side, rinsing and drying, application of the universal adhesive Prime Bond active with a microbrush. The adhesive is blown from the cervical to the incisal edge and cured for 20 seconds per side
- Application of a Ceram.x duo SphereTEC™E2 shade enamel mass. A Teflon sheet is placed on the surface to stamp the enamel mass deposited on the surface. The stamp is removed, the excess composite is removed, a marginal finish is done with a brush; the composite is finally polymerized.
- Polishing and glossing of composites with the Enhance® / Enhance® PoGo® system

Discussion and Conclusion

Composite resin restorations are indicated for global changes in the shape of the teeth, as they allow for maximum preservation of the underlying dental tissue. The preliminary analysis and the realization of a careful wax-up allow to realize a guided approach thanks to transfers (stamp).

This technique compared to :

- Indirect restorations → does not need any preparation of the tooth,
- Injected flowable composite → gives better mechanical properties,
- Regular direct composite restoration → offers a better control of the morphology.

Dentsply
Sirona

Academy